Pediatric Dental Trauma

How to manage its trauma in MDS Examination

Indian Society of Dental Traumatology

Dr Nitesh Tewari
MDS, FIADT (USA)
Associate Professor
Pedodontics & Preventive Dentistry
Centre For Dental Education and Research
All India Institute of Medical Sciences, New Delhi

Pediatric Dental Trauma

How to manage its trauma in MDS Examination

Indian Society of Dental Traumatology

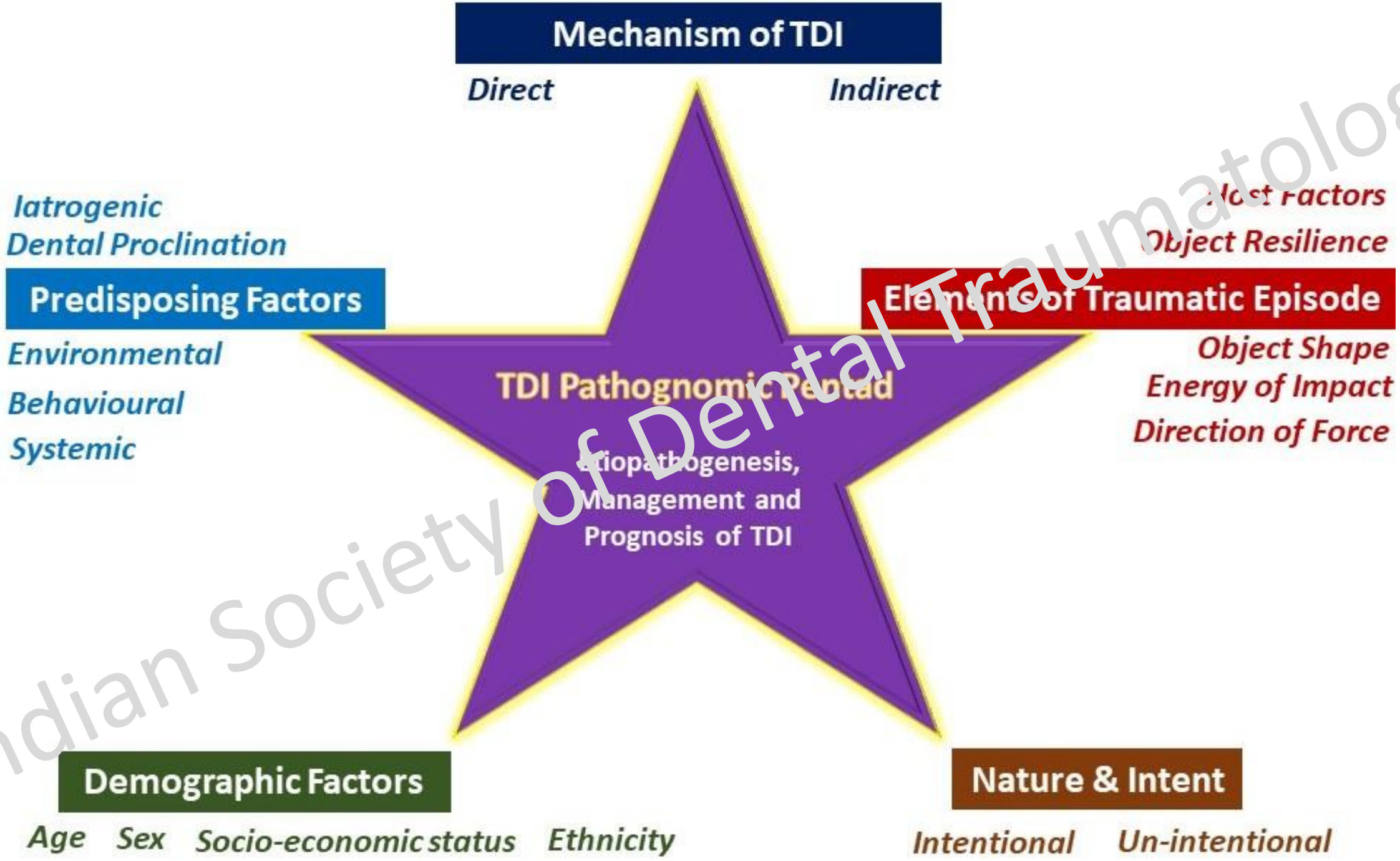

Indian Society of Dental Traumatology

TDI Evaluation Algorithm

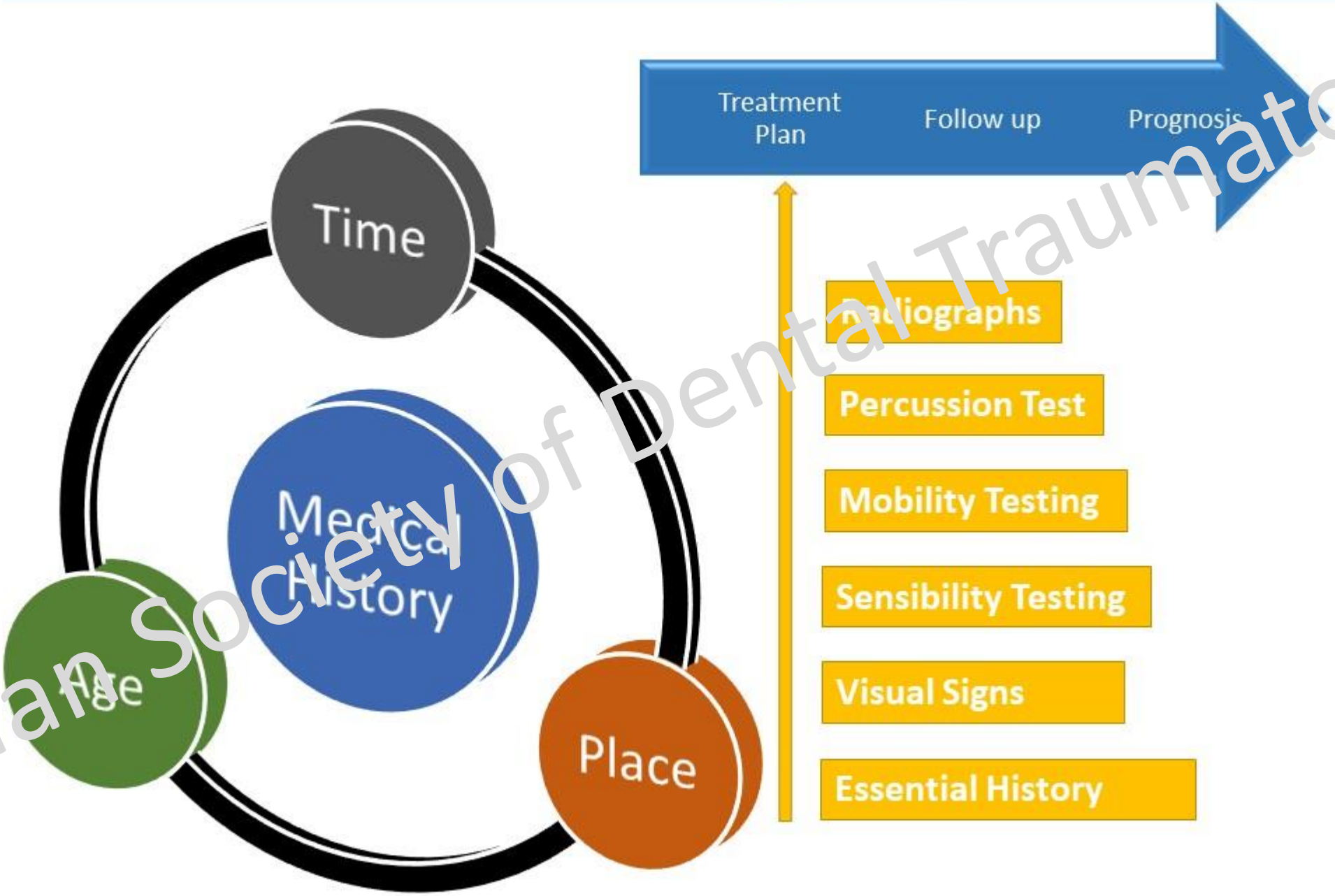

Indian Society of Dental Traumatology

Classifications

Classification by Rabinowitch (1956)
Traumatic Dental Injuries of Primary Teeth
1. Fractures of the enamel or slightly into the dentin
2. Fractures into the dentin
3. Fractures into the pulp
4. Fractures of the root
5. Comminuted fractures
6. Displaced teeth

Classification by Ulfon (1985)
Traumatic Dental Injuries from Clinical/ Endodontic point of view: Crown Fractures only & without radiographs
A. Fracture of enamel
B. Fracture of the crown with indirect pulp exposure through the dentin.
C. Fracture of the crown with direct pulp exposure.

Ellis and Davey's Classification (1960)
Traumatic Dental Injuries of Primary Teeth
Class 1- Simple fracture of the crown involving little or no dentin.
Class 2- Extensive fracture of the crown involving considerable dentin, but not the dental pulp.
Class 3- Extensive fracture of the crown involving considerable dentin and exposing the dental pulp.
Class 4- The traumatized teeth that become non-vital with or without a loss of crown structure.
Class 5- Teeth lost as a result of trauma.
Class 6- Fracture of the root with or without a loss of the crown structure.
Class 7- Displacement of a tooth without fracture of the crown or root.
Class 8- Fracture of crown en masse and it's replacement.
Class 9- Traumatic injuries to primary teeth.

Indian Society of Dental Traumatology

WHO Classification (1978 & 1995)
873.60 - Fracture of Enamel with only Enamel chipping.
873.61- Fracture of crown of tooth with Enamel & Dentin without pulpal involvement.
873.62- Fracture of crown of tooth with pulpal involvement.
873.63- Fracture of root of tooth.
873.64- Fracture of crown with root of tooth.
873.66 - Tooth concussion – sensitive to percussion, subluxation – loosening
873.67- Intrusion or Extrusion
873.68- Avulsion or Exarticulation
873.69- Other injuries – including laceration of soft tissues.

International classification of diseases to dentistry and stomatology (1995)

S02- Fracture of skull and facial bones

- S02.4- Fracture of malar and maxillary bones
- S02.5- Fracture of tooth - includes primary (deciduous) and permanent teeth
- S02.50 - Fracture of enamel of tooth only Enamel chipping
- S02.51 - Fracture of crown of tooth without pulpal involvement
- S02.52 - Fracture of crown of tooth with pulpal involvement
- S02.53 - Fracture of root of tooth
- S02.54 - Fracture of crown with root of tooth
- S02.57 - Multiple fractures of teeth

S03- Dislocation, sprain and strain of joints and ligaments of head

- S03.0- Dislocation of jaw
- S03.1- Dislocation of septal cartilage of nose
- S03.2- Dislocation of tooth
  - S03.20- Luxation of tooth
  - S03.21- Intrusion or extrusion of tooth
  - S03.22- Avulsion of tooth (exarticulation)

Indian Society of Dental Traumatology

Modification of Ellis Classification by Mc Donald, Avery and Lynch (1983)
Class 1: Simple fracture of the crown involving little or no dentin.
Class 2: Extensive fracture of the crown involving considerable dentin, but not the dental pulp.
Class 3: Extensive fracture of the crown with an exposure of the dental pulp.
Class 4: Loss of the entire crown.

Garcia-Godoy's Classification for Traumatic Injuries (1981)
Numeric Modified from WHO-1978
Class 0- Enamel Crack
Class 1- Enamel Fracture
Class 2- Enamel-dentin fracture without pulpal exposure.
Class 3- Enamel-dentin fracture with pulpal exposure
Class 4- Enamel-dentin-cementum fracture without pulpal exposure
Class 5- Enamel –dentin-cementum fracture with pulpal exposure
Class 6- Root fracture
Class 7- Concussion
Class 8- Luxation (loosening)
Class 9- Lateral displacement
Class 10- Intrusion
Class 11- Extrusion
Class 12- Avulsion

Indian Society of Dental Traumatology

Pulver's Classification of Traumatic Injuries (1982)
Descriptive Classification for Combination Trauma
Class I Division I- No external fracture, no displacement Division II- No fracture but displacement Division III- Fracture of enamel only, no displacement Division IV- Fracture of enamel and displacement
Class II Division I- Fracture of enamel and dentin only, no displacement Division II- Fracture of enamel and dentin only with displacement
Class III Division I- Fracture (with exposure of pulp), no displacement Division II- Fracture (with exposure of pulp) and displacement
Class IV Division I- Fracture of root
Class V Division I- Intrusion Division II- Partial avulsion Division III- Complete avulsion

Indian Society of Dental Traumatology

Descriptive Classification

Andreasen's Classification (1981)

A. Injuries to hard dental tissues and pulp

Enamel infraction- An incomplete fracture (crack) of the enamel without loss of tooth substance.

Enamel fracture (Uncomplicated crown fracture)- A fracture with loss of enamel only.

Enamel–dentin fracture (Uncomplicated crown fracture)- A fracture with loss of enamel and dentin, but not involving the pulp.

Complicated crown fracture- A fracture involving enamel and dentin, and exposing the pulp.

Uncomplicated Crown–root fracture- A fracture involving enamel, coronal and radicular dentin, and cementum

Complicated Crown-root fracture- A fracture involving enamel, coronal and radicular dentin, cementum and exposing the pulp.

Root fracture- A fracture involving radicular dentin, cementum, and the pulp.

C. Injuries to gingiva or oral mucosa

Enamel infraction- An incomplete fracture (crack) of the enamel without loss of tooth substance.

Contusion of gingival or oral mucosa- A bruise usually produced by impact with blunt object and not accompanied by a break in mucosa but usually causing submucosal hemorrhage.

Abrasion of gingival or oral mucosa- Superficial wound produced by rubbing or scrapping of mucosa leaving a raw bleeding surface

B. Injuries to periodontal tissues

Concussion- An injury to the tooth-supporting structures without abnormal loosening or displacement of the tooth, but with increased reaction to percussion.

Subluxation (Loosening) - An injury to the tooth supporting structures with abnormal loosening but without displacement of the tooth.

Extrusive luxation (peripheral dislocation, partial avulsion)- Partial displacement of the tooth out of its socket.

Lateral luxation. Displacement of the tooth in a direction other than axial. This is accompanied by comminution or fracture of the alveolar socket.

Intrusive luxation (central dislocation)- Displacement of the tooth into the alveolar bone. This injury is accompanied by comminution or fracture of the alveolar socket.

Avulsion (exarticulation)- Complete displacement of the tooth out of its socket.

D. Injuries to supporting bone

Comminution of alveolar socket wall- Crushing and compression of the alveolar socket. As in intrusion & lateral luxation.

Fractures of alveolar socket wall- A fracture contained to the facial or lingual socket wall.

Fractures of maxillary or mandibular alveolar process– A fracture of the alveolar process which may or may not involve the alveolar socket.

Fractures of the mandible or maxilla- A fracture involving the base of the mandible or maxilla and often the alveolar process (jaw fracture). The fracture may or may not involve the alveolar socket.

Indian Society of Dental Traumatology

	Clinical Features	Investigations	Treatment	Follow up	Prognosis & Sequelae
Enamel Infraction					
Primary Dentition	Often not reported by parents/care givers and not associated with any pain. Association with any other type of TDI is rare.	No investigation is required	No treatment has been recommended in most cases except for smoothening of edges. Although in Indian situations, sealing by flowable composite or glass ionomer can be done due to poor patient compliance for follow ups.	No follow up recommended, although tooth's status along with restoration must be evaluated in every routine follow up visit.	Prognosis- Its prognosis is good unless associated with any other TDI. No long term sequelae of primary tooth enamel infraction has been reported in associated succedaneous tooth.
Permanent Dentition	Solitary to Multiple cracks or craze lines appear on the tooth surface. Patients are sometimes even unaware of this injury with stains percolating in the defects in long standing cases. It is not painful unless associated with another TDI as root fracture and luxation injury.	No investigation as IOPA radiograph or pulp testing is required unless any other painful sign is observed.	In case of widespread or deep crazing, a composite restoration is done to restore esthetics and prevent future discoloration of infraction lines. Some times, especially in localised superficial crazing, no treatment is necessary.	No follow up is required unless associated with any other TDI. However the status of restored tooth/teeth must be evaluated in routine dental check ups.	Favourable prognosis is indicated for asymptomatic teeth with intact restoration. However undetected TDI, other associated traumas and Multiple dental trauma episodes (MDTE) can lead to loss of vitality, discoloration and apical periodontitis which require stage appropriate endodontic management.
Enamel Fracture (Uncomplicated Crown Fracture)- (Ellis Class I for Permanent Dentition)					
Primary Dentition	This TDI involved loss of enamel without any sign of dentin or pulpal involvement. It might be associated with other injuries as root fracture or luxation causing pain or mobility.	No investigation is required unless associated with any other TDI.	Sealing of enamel defect with glass ionomer cement (GIC) is recommended. Composite resin restoration can be done if longevity of GIC is questionable or lost edge or angle is large.	A clinical evaluation after 3-4 weeks	Enamel fractures have good prognosis after treatment, however, MDTEs and associated TDI can lead to further damage of tooth and supporting structures requiring endodontic intervention. No long term sequelae reported.
Permanent Dentition	It is associated with enamel loss in form of fractured incisal edge or angle without any dentin or pulpal involvement. Pain if present is secondary to any other associated TDI as root fracture or luxation.	No investigations are usually required. IOPA radiographs and pulp testing may be needed for associated injuries. If soft tissue trauma along with enamel fracture, must be radiographed to search for fractured fragment.	Treatment of choice is "Fragment Reattachment". It requires stability during composite bonding. Composite resin build up can be done when fragment is not available.	A follow up of 6-8 weeks followed by 1 year with clinical and radiographic evaluation.	Enamel fractures, without other injuries have good prognosis. However unreported TDI, associated traumas and Multiple dental trauma episodes (MDTE) can lead to adverse outcomes as loss of vitality, discoloration and apical periodontitis.
Enamel–dentin fracture (Uncomplicated crown fracture)- (Ellis Class II for Permanent Dentition)					
Primary Dentition	It involves loss of crown structure with exposure of dentinal surface and hence may be associated with transient sensitivity to cold. Tooth may be painful when associated with luxation or root fracture.	Radiographs are not needed in absence of loss of crown structure and without any other TDI. Soft tissue radiographs might be needed for ruling out any embedded fractured fragment.	Recommended treatment is to seal the exposed dentin with glass ionomer cement to prevent microleakage and prevent sensitivity. Fragment reattachment can be done if patient comes with fractured portion. In dentin fractures close to pulp, within 0.5 mm (pink, no bleeding), calcium hydroxide liner is placed and covered with direct bonding material as GIC. Use of composite resin in cooperative children can lead to better esthetic results. Large fractures can be treated with strip crowns and other full coverage esthetic alternatives as veneered stainless steel crowns and pediatric zirconia crowns. One important thing not to be missed is removal of plaque biofilm from the fractured surface, especially when there is a treatment delay. Presence of biofilm results in faulty sealing, marginal leakage and loss of restoration.	A clinical evaluation after 3-4 weeks has been recommended for follow up.	It has good prognosis after treatment, however, MDTEs and associated TDI can lead to adverse effects. No long term sequelae of primary tooth enamel-dentin fracture have been reported in associated succedaneous tooth. (Figure 6&7)

Indian Society of Dental Traumatology

Management Charts

www.iadt.org
www.isdt.in

How to attempt DT Theory Questions?

Essay Questions:

Q.1. Traumatic Dental Injuries

Expectations:

Discuss the entire section of TRAUMATIC DENTAL INJURIES **ONLY**

Structured Answer with Diagrams, references and details

Avoidance of irrelevant discussion

Assume it as your Library dissertation

Indian Society of Dental Traumatology

Structure-

- **Introduction:** Traumatic Dental Injuries- Definitions (cite author)
- **Epidemiology:** Global, Indian, Quantum Comparison with Maxillofacial Trauma, Age of predilection, Bimodal peaks in males (cite authors)
- **Type of Trauma:** Direct & Indirect, Primary tooth and Permanent Tooth
- **Etiopathogenesis:** Sources and conditions (cite authors)
- **Classification:** Don’t Limit to Ellis and Andreasen’s only

Indian Society of Dental Traumatology

- **Management** (Discuss based on IADT 2012 Guidelines)
  - Emergency evaluation- History, Radiographs, Emergency Instructions
  - Management-

  Based on Andreasen's Classification- Primary & Permanent

  (Definition, Clinical Features, Radiographic Features, investigations, management, Follow up, SEQUELAE)

  Draw Diagrams
- **Trauma Prevention** (cite Authors)
- **Trauma Awareness** (Compare studies and Clinical Decision Support tools briefly)
- **Conclusion**

Indian Society of Dental Traumatology

How to attempt DT Theory Questions?

Essay Questions:

Q.2. Luxation injuries

Expectations:

Discuss the entire section of LUXATION INJURIES **ONLY**

Structured Answer with Diagrams, references and details

Avoidance of irrelevant discussion

Assume it as your Library dissertation

Indian Society of Dental Traumatology

Structure-

- **Introduction:** Luxation Injuries- Definition (cite author)

Describe how other classifications deal with this type of injury

- **Epidemiology:** Global, Indian, Association with panfacial Trauma, Age of predilection, (cite authors)
- **Etiopathogenesis:** Sources and conditions (cite authors)
- **Classification:** With Diagrams- Describe only with Andreasen's Classification
  - Concussion
  - Subluxation
  - Lateral Luxation
  - Extrusive Luxation
  - Intrusive Luxation
  - Avulsion
  - **Combination Luxation Injuries**

Indian Society of Dental Traumatology

- **Management** (Discuss based on IADT 2012 Guidelines)
  - Emergency evaluation- History, Radiographs, Emergency Instructions
  - Management-

  Based on Andreasen's Classification- Primary & Permanent

  (Definition, Clinical Features, Radiographic Features, investigations, management, Follow up, SEQUELAE)

  Description of sequelae is important in this question due to high incidence

  Draw Diagrams
- **Prevention of Luxation injuries**- Sports Dentistry (cite Authors)
- **Trauma Awareness** (Compare studies and Clinical Decision Support tools briefly)
- **Conclusion**

Indian Society of Dental Traumatology

How to attempt DT Theory Questions?

Essay Questions:

Q.3. Management of Tooth Avulsion

Expectations:

Discuss the entire section of TOOTH AVULSION **ONLY**

Base your answer on IADT Guideline 2012 but describe details from all sources

Structured Answer with Diagrams, references and details

Avoidance of irrelevant discussion

Assume it as your Library dissertation

Indian Society of Dental Traumatology

Structure-

- **Introduction:** Avulsion Injuries- Definition (cite author)

Describe how other classifications deal with this type of injury

- **Epidemiology:** Global, Indian, Association with panfacial Trauma, Age of predilection (cite authors)
- **Etiopathogenesis:** Sources and conditions (cite authors)
- **Emergency evaluation and considerations**
- **Emergency instructions**
- **Detailed management**

Indian Society of Dental Traumatology

- **Detailed Management** (Discuss based on IADT 2012 Guidelines)
  - Management of Avulsed Primary tooth

  (investigations if tooth can be accounted for or there is risk of aspiration, management, Follow up, SEQUELAE)

  Management of immediate reported cases- Replantation controversy?

  (cite two systematic reviews)

  Management of delayed reported cases- rehabilitation and space management

  Description of sequelae

  Draw Diagrams

Indian Society of Dental Traumatology

- **Detailed Management (Discuss based on IADT 2012 Guidelines)**
  - Management of Avulsed Permanent tooth

  (investigations if tooth can be accounted for or there is risk of aspiration, management, Follow up, Sequelae management)

  Management of immediate reported cases-

  Six Scenarios

  1. **Self replanted- Closed Apex**
  2. **Closed Apex- Extra oral Dry time <60 min**
  3. **Closed Apex- Extra oral Dry time >60 min**
  4. **Self replanted- Open Apex**
  5. **Open Apex- Extra oral Dry time <60 min**
  6. **Open Apex- Extra oral Dry time >60 min**

  Discuss: Splinting (Studies)

  Discuss: Tooth Storage Medium (Studies)

  Discuss: Sequelae as External Inflammatory Root Resorption and Ankylosis and their management

  Management of delayed reported cases- Autotransplantation, rehabilitation using Fibre reinforced bridge, Implants

  Draw Diagrams

Indian Society of Dental Traumatology

How to attempt DT Theory Questions?

Long Questions:

Q. Direct Questions for management

Expectations:

Discuss the entire section of TOOTH TRAUMA ASKED **ONLY**

Descriptive Classification with details from all sources

Structured Answer with Diagrams, references and details

Avoidance of irrelevant discussion

Indian Society of Dental Traumatology

Questions have been for Permanent Dentition mostly

- Management of- Ellis Class III to VI
- Management of Crown Fracture with Vital pulp- (Must Discuss both open and closed apex along with combination trauma)
- Management of Crown Fracture with Non Vital Pulp- Same
- Management of Root Fracture
- Management of Avulsed permanent tooth
- Primary tooth trauma

Indian Society of Dental Traumatology

Structure

- **Introduction:** Define the condition (cite author)

Describe how other classifications deal with this type of injury

- **Epidemiology:** Global, Indian, Association with panfacial Trauma, Age of predilection in short (cite authors)
- **Etiopathogenesis:** Sources and conditions (cite authors)
- **Emergency evaluation and considerations**
- **Emergency instructions**
- **Detailed management**

Indian Society of Dental Traumatology

- **Management** (Discuss based on IADT 2012 Guidelines)
  - Emergency evaluation- History, Radiographs, Emergency Instructions
  - Management-

  Based on Andreasen's Classification-

  (Definition, Clinical Features, Radiographic Features, investigations, management, Follow up, SEQUELAE)

  Draw Clear and explanatory Diagrams
- **Prevention of injuries**- brief (cite Authors)
- **Trauma Awareness** brief (Compare studies and Clinical Decision Support tools briefly)
- **Conclusion**

Indian Society of Dental Traumatology

How to attempt DT Theory Questions?

Long Questions:

Q. Case Scenario Based Questions for management

Expectations:

Decipher the Case into simple description

Discuss the entire section of TOOTH TRAUMA ASKED **ONLY**

Descriptive Classification with details from all sources

Structured Answer with Diagrams, references and details

Avoidance of irrelevant discussion

Indian Society of Dental Traumatology

Q. Discuss the management of Ellis Class III Fracture in an 12 year old boy reporting to the dentist after two hours of trauma.

Q. Discuss the management of Crown Fracture in an 12 year old boy reporting to the dentist after two hours of trauma.

Q. Discuss the management of Crown Fracture in an 8 year old boy reporting to the dentist after two hours of trauma.

Q. Discuss the management of Crown Fracture in an 12 year old boy reporting to the dentist after two weeks of trauma.

Q. Discuss the management of Avulsion in an 9 year old girl reporting to the dentist in 4 hours of trauma with tooth stored in paper towel.

Indian Society of Dental Traumatology

SEE-TYPE, **A**SSESS- AGE, **C**ONFIRM- TIME, **A**NALYSE- SPECIAL CONDITIONS

How to prepare & attempt DT Theory Questions?

Short Notes:

Q. Trauma management Specific Questions

Expectations:

To the point

Discuss the specific aspect of TOOTH TRAUMA ASKED **ONLY**

Structured Answer (Mostly) with Diagrams and references

NO irrelevant discussion

Indian Society of Dental Traumatology

Questions have been for

- Splinting
- Tooth Storage Media
- Intrusive Luxation
- Extrusive Luxation
- External Root Resorption
- Long term sequelae to primary tooth trauma
- Decoronation
- Autotransplantation

Indian Society of Dental Traumatology

How to prepare & attempt DT Theory Questions?

Short Notes:

Q. Treatment Modality based Questions

Expectations:

To the point

Discuss the specific aspect of Treatment **ONLY**

Discuss its relevance in trauma management

Structured Answer (Mostly) with Diagrams and references

NO irrelevant discussion

Indian Society of Dental Traumatology

Questions have been for

- Revascularisation
- MTA/Biodentin
- Apical Barrier Technique
- Apexification
- Apexogenesis
- Apexification vs Apexogenesis
- Pulp Vitality Testing
- Pulse Oximetry
- Tri Antibiotic Paste
- Stem Cells in Dentistry/ Regenerative Dentistry

Indian Society of Dental

Common Errors in attempting DT Theory Questions

- Lack of structure
- Lack of Diagrams
- Confusion regarding which BOOK to follow
- Habit of writing unnecessary details
- Taking it TOO easy
- Lack of references

Indian Society of Dental Traumatology

The Viva Voce and Pedagogy questions

- Most of the questions discussed in short questions
- Dental Trauma Guide (www.dentaltraumaguide.org)
- Root canal disinfection
- Recent articles **(best strategy)**

Common Errors:

- Deviating from what has been asked
- *Mis*-leading the questions
- Missing the IADT Guidelines

Indian Society of Dental Traumatology

Some Important Articles (NOT TO BE MISSED)

Indian Society of Dental Traumatology

Guidelines

International Association of Dental Traumatology

Australian Society Of ENDODONTOLOGY

- **Diagnosis**
- **Management**
- **Follow-up**
- **CROSS REFERENCES**

Dental Traumatology

Dental Traumatology 2012; **28**: 2–12; doi: 10.1111/j.1600-9657.2011.01103.x

International Association of Dental Traumatology guidelines for the management of traumatic dental injuries: 1. Fractures and luxations of permanent teeth

Anthony J. DiAngelis*[1], Jens O. Andreasen*[2], Kurt A. Ebeleseder*[3], David J. Kenny*[4], Martin Trope*[5], Asgeir Sigurdsson*[6], Lars Andersson[7], Cecilia Bourguignon[8], Marie Therese Flores[9], Morris Lamar Hicks[10], Antonio R. Lenzi[11], Barbro Malmgren[12], Alex J. Moule[13], Yango Pohl[14], Mitsuhiro Tsukiboshi[15]

Abstract – Traumatic dental injuries (TDIs) of permanent teeth occur frequently in children and young adults. Crown fractures and luxations are the most commonly occurring of all dental injuries. Proper diagnosis, treatment planning and followup are important for improving a favorable outcome. Guidelines should assist dentists and patients in decision making and for providing the best care effectively and efficiently. The International Association of Dental Traumatology (IADT) has developed a consensus statement after a review of the dental literature and group discussions. Experienced researchers and clinicians from various specialties were included in the group. In cases where the data did not appear conclusive, recommendations were based on the

Indian Society of Dental Traumatology

https://www.iadt-dentaltrauma.org/1-9%20%20iadt%20guidelines%20combined%20-%20lr%20-%2011-5-2013.pdf

Trauma Epidemiology

Accepted: 8 February 2018

DOI: 10.1111/edt.12389

COMPREHENSIVE REVIEW

WILEY Dental Traumatology

World traumatic dental injury prevalence and incidence, a meta-analysis—One billion living people have had traumatic dental injuries

Stefano Petti[1] | Ulf Glendor[2] | Lars Andersson[3]

[1]Department of Public Health and Infectious Diseases, Sapienza University, Rome, Italy

[2]Faculty of Odontology, Malmö University, Malmö, Sweden

[3]Department of Surgical Sciences, Faculty of Dentistry, Health Sciences Center, Kuwait University, Kuwait City, Kuwait

Correspondence
Stefano Petti, Department of Public Health and Infectious Diseases, Sapienza University, Rome, Italy.
Email: stefano.petti@uniroma1.it

Abstract

Traumatic dental injuries (TDIs) account for a considerable proportion of bodily injuries. Nevertheless, global TDI frequency is unknown, probably because TDI diagnosis is not standardized. This study estimated world TDI frequency. A literature search (publication years 1996-2016) was aimed at covering as many countries, communities, ethnic groups as possible, thus achieving high generalizability. In particular, non-specific keywords, no language restrictions, and large databanks were used. Observational studies reporting proportions of individuals with at least one TDI (prevalence) and who developed TDI (incidence rate) were considered. Prevalence

THE LANCET
Global Health

Log in Register

CORRESPONDENCE | VOLUME 6, ISSUE 10, PE1070-E1071, OCTOBER 01, 2018

PDF [41 KB] Save Share Reprints Request

The fifth most prevalent disease is being neglected by public health organisations

Stefano Petti • Jens Ove Andreasen • Ulf Glendor • Lars Andersson

Open Access • Published: October, 2018 • DOI: https://doi.org/10.1016/S2214-109X(18)30300-2

PlumX Metrics

References

Article Info

The progress towards reduction of global mortality has produced an epidemiological transition towards non-fatal diseases, which challenge the ability of the world's population to live in full health. Although traumatic dental injuries are not lethal, their treatment is more expensive (US$2 000 000–5 000 000 per million inhabitants)

ADVERTISEMENT

Feedback

Indian Society of Dental Traumatology

- Andreasen JO, Ravn JJ. Epidemiology of traumatic dental injuries to primary and permanent teeth in a Danish population sample. Int J Oral Surg 1972;1:235–9.
- Glendor U. Epidemiology of traumatic dental injuries-a 12 year review of the literature. Dent Traumatol. 2008;24:603-611.

Clin Oral Investig. 2017 Nov;21(8):2415-2420. doi: 10.1007/s00784-016-2037-3. Epub 2016 Dec 2

Does dental trauma in the primary dentition increases the likelihood of trauma in the permanent dentition? A longitudinal study.

Goettems ML[1], Brancher LC[2], da Costa CT[2], Bonow MLM[2], Romano AR[2].

Australian Dental Journal
The official journal of the Australian Dental Association
ADA AUSTRALIAN DENTAL ASSOCIATION INC.
Australian Dental Journal 2016; 61:(1 Suppl): 4–20
doi: 10.1111/adj.12395

Epidemiology and outcomes of traumatic dental injuries: a review of the literature

R Lam*

Indian Society of Dental Traumatology

Oral Health Prev Dent • ISSN 1602-1622

Oral Health and Preventive Dentistry

QUINTESSENCE PUBLISHING

All journals Latest issues SignIn Contact

Oral Health Prev Dent 9 (2011), No. 3 17. Oct. 2011

Oral Health Prev Dent 9 (2011), No. 3 (17.10.2011)

Page 301-305, doi:10.3290/j.ohpd.a22339, PubMed:22068187

Prevalence of Traumatic Dental Injuries Among 12- to 15-year-old Schoolchildren in Ambala District, Haryana, India

Kumar, Adarsh / Bansal, Vikram / Veeresha, Koratagere Lingappa / Sogi, Girish M.

Int J Clin Pediatr Dent. 2015 Sep-Dec;8(3):172-5. doi: 10.5005/jp-journals-10005-1308. Epub 2015 Sep 11.

Prevalence and Etiology of Traumatic Injuries to the Anterior Teeth among 5 to 8 Years Old School Children in Mathura City, India: An Epidemiological Study.

Gojanur S[1], Yeluri R[2], Munshi AK[3].

Oral Health Dent Manag. 2013 Mar;12(1):17-23.

Traumatic injuries in the primary teeth of 4- to 6-year-old school children in gulbarga city, India. A prevalence study.

Bhayya DP[1], Shyagali TR.

Indian Society of Dental Traumatology

Etiopathogenesis

Dental Traumatology

Dental Traumatology 2009; **25**: 19–31; doi: 10.1111/j.1600-9657.2008.00694.x

Aetiology and risk factors related to traumatic dental injuries – a review of the literature

Ulf Glendor

Division of Social Medicine and Public Health Science, Department of Medicine and Society, Linköping University, Linköping, Sweden

Abstract – *Background/Aim:* During the past 30 years, the number of aetiologies of traumatic dental injuries (TDIs) has increased dramatically in the literature and now includes a broad spectrum of variables, including oral and environmental factors and human behaviour. The aim of this study is to present an international review of well-known as well as less well-known unintentional and intentional causes of TDIs. Moreover, some models that are useful in investigating contact sport injuries are presented.

Materials and methods: The databases of Medline, Cochrane, Social Citation Index, Science Citation Index and CINAHL from 1995 to the present were used.

Result: Oral factors (increased overjet with protrusion), environmental determinants (material deprivation) and human behaviour (risk-taking children, children being bullied, emotionally stressful conditions, obesity and attention-deficit hyperactivity disorder) were found to increase the risk for TDIs. Other factors increasing the risk for TDIs are presence of illness, learning difficulties, physical limitations and inappropriate use of teeth. A new cause of TDIs that is of particular interest is oral piercing. In traffic facial injury was similar in unrestrained occupants (no seat belts) and occupants restrained only with an air

Indian Society of Dental Traumatology

Community Dent Oral Epidemiol. 2014 Dec;42(6):581-90. doi: 10.1111/cdoe.12113. Epub 2014 Jun 11

Dental trauma: prevalence and risk factors in schoolchildren.

Goettems ML[1], Torriani DD, Hallal PC, Correa MB, Demarco FF.

Dent Traumatol. 2015 Jun;31(3):177-83. doi: 10.1111/edt.12167. Epub 2015 Mar 25.

Clarifying the effect of behavioral and clinical factors on traumatic dental injuries in childhood: a hierarchical approach.

Kramer PF[1], Feldens EG, Bruch CM, Ferreira SH, Feldens CA.

Indian Society of Dental Traumatology

Long-term sequelae to Primary TDI on Permanent Dentition

1. Andreasen JO, Sundstrom B, Ravn JJ. The effect of traumatic injuries to primary teeth on their permanent successors I. A clinical and histologic study of 117 injured permanent teeth. Scand J Dent Res. 1971;79:219-283.
2. Andreasen JO, Ravn JJ. The effect of traumatic injuries to primary teeth on their permanent successors II. A clinical and radiographic follow-up study of 213 teeth. Scand J Dent Res. 1971;79:284-294
3. von Arx T. Developmental disturbances of permanent teeth following trauma to the primary dentition. Aust Dent J. 1993;38:1-10.
4. Holan G, Needleman HL. Premature loss of primary anterior teeth due to trauma – potential short and long-term sequelae. Dent Traumatol. 2014;30:100-106.

Indian Society of Dental Traumatology

Dental Traumatology

Explore this journal >

Original Article

Long term effects of traumatic dental injuries of primary dentition on permanent successors: a retrospective study of 596 teeth

Nitesh Tewari, Vijay Prakash Mathur, Neeraja Singh, Subash Singh, Ramesh Kumar Pandey

Accepted manuscript online: 1 March 2018 Full publication history

DOI: 10.1111/edt.12391 View/save citation

Cited by (CrossRef): 0 articles Check for updates Citation tools

Altmetric Score

Accepted Articles

Browse Accepted Articles

Accepted, unedited articles published online and citable. The final edited and typeset version of record will appear in future.

This article has been accepted for publication and undergone full peer review but has not been through the copyediting, typesetting, pagination and proofreading process, which may lead to differences between this version and the Version of Record. Please cite this article as doi: 10.1111/edt.12391

Indian Society of Dental Traumatology

Revascularisation & Regenerative Dentistry

Functional biomaterials and extracellular matrices for dental tissue repair and regeneration

Journal of Tissue Engineering
Volume 10: 1–13
© The Author(s) 2019
rticle reuse guidelines:
om/journals-permissions
.1177/2041731418819263
ls.sagepub.com/home/tej
SAGE

Pulp-dentin regeneration: current approaches and challenges

Chanyong Jung[1,2], Sangwan Kim[2], Taeuk Sun[2], Yong-Bum Cho[2] and Minju Song[2]

Abstract

Regenerative endodontic procedures for immature permanent teeth with apical periodontitis confer biological advantages such as tooth homeostasis, enhanced immune defense system, and a functional pulp-dentin complex, in addition to clinical advantages such as the facilitation of root development. Currently, this procedure is recognized as a paradigm shift from restoration using materials to regenerate pulp-dentin tissues. Many studies have been conducted with regard to stem/progenitor cells, scaffolds, and biomolecules, associated with pulp tissue engineering. However, preclinical and clinical studies have evidently revealed several drawbacks in the current clinical approach to revascularization that may lead to unfavorable outcomes. Therefore, our review examines the challenges encountered under clinical conditions and summarizes current research findings in an attempt to provide direction for transition from basic research to clinical practice.

Pulp Revascularization or Apexification for the Treatment of Immature Necrotic Permanent Teeth: Systematic Review and Meta-Analysis

Gabriel Ferreira Nicoloso*/ Gabriela Maltz Goldenfum**/Tatiane da Silva Dal Pizzol***/ Roberta Kochenborger Scarparo****/ Francisco Montagner*****/ Jonas de Almeida Rodrigues******/ Luciano Casagrande*******

- Ostby NB, Hjortdal O. Tissue formation in the root canal following pulp removal Scand. J Dent Res 1971;79(5):333-349.
- Hargreaves KM, Giesler T, Henry M, Wang Y. Regenerative potential of the young permanent tooth: what does the future hold? J Endod 2008;34(7S):s51-s56.
- Banchs F, Trope M. Revascularization of immature permanent teeth with apical periodontitis new treatment protocol. J Endod 2004;30(4):196-200.
- Trope M. Treatment of the immature tooth with nonvital pulp and apical periodontitis. Dent Clin North Am 2010;54(2): 313-324
- Hoshino E, Kurihara-Ando N, Sato I, Uematsu H, Sato M, Kota K, Iwaku M. In vitro antibacterial susceptibility of bacteria taken from infected root dentine to a mixture of ciprofloxacin, metronidazole and minocycline. Int Endod J 1996;29(2): 125-130.

J Endod. 2017 Jul;43(7):1052-1057. doi: 10.1016/j.joen.2017.03.003. Epub 2017 May 13.

An Evidence-based Review of the Efficacy of Treatment Approaches for Immature Permanent Teeth with Pulp Necrosis.

Kahler B[1], Rossi-Fedele G[2], Chugal N[3], Lin LM[4].

INTERNATIONAL ENDODONTIC JOURNAL
doi:10.1111/iej.12606

REVIEW

Clinical procedures for revitalization: current knowledge and considerations

Journal of Dental Research
IADR International Association for Dental Research
AADR American Association for Dental Research

Home | Browse | Submit Paper | About | Subscribe

Pulp Vascularization during Tooth Development, Regeneration, and Therapy

C. Rombouts*, T. Giraud*, C. Jeanneau, more... Show all authors

First Published October 10, 2016 | Review Article | Check for updates

Front Physiol. 2016; 7: 58. PMCID: PMC4779938
Published online 2016 Mar 7. doi: 10.3389/fphys.2016.00058

Pulp Regeneration: Current Approaches and Future Challenges

Jingwen Yang,[1,2] Guohua Yuan,[1,2] and Zhi Chen[1,*]

Dent Update. 2015 Jul-Aug;42(6):556-8, 560-1.

Current Applications and Future Prospects of Stem Cells in Dentistry.

Surendran S, Sivamurthy G.

Root Fracture Healing

- J. O. Andreasen, F. M. Andreasen, I. Mejare, and M. Cvek, “Healing of 400 intra-alveolar root fractures. 1. Effect of preinjury and injury factors such as sex, age, stage of root development, fracture type, location of fracture and severity of dislocation,” Dental Traumatology, vol. 20, no. 4, pp. 192–202, 2004
- J. O. Andreasen, S. S. Ahrensburg, and G. Tsilingaridis, “Root fractures: the influence of type of healing and location of fracture on tooth survival rates—an analysis of 492 cases,” Dental Traumatology, vol. 28, no. 5, pp. 404–409, 2012
- J. J. May, N. Cohenca, and O. A. Peters, “Contemporary management of horizontal root fractures to the permanent dentition: diagnosis-radiologic assessment to include conebeam computed tomography,” Journal of Endodontics, vol. 39, no. 3, pp. S20–S25, 2013.

Apexification, MTA & Apical Barrier

A. Agrafioti, D.G. Giannakoulas*, C.G. Filippatos, E.G. Kontakiotis

Department of Endodontics, School of Dentistry, National and Kapodistrian University of Athens, Athens, Greece
**School of Dentistry, National and Kapodistrian University of Athens, Athens, Greece*

email: agrafiot@dent.uoa.gr

DOI: 10.23804/ejpd.2017.18.04.03

Analysis of clinical studies related to apexification techniques

ABSTRACT

Introduction

Teeth with necrotic pulp and open apex bring about several challenges to clinicians due to the lack of natural apical constriction and the thin root walls that are prone to fracture [Trope, 2006, Camp, 2008]. In order to confine filling materials into the root canal space and prevent overfilling, the placement of an artificial apical barrier and/or the closure of the apex are necessary before obturation of the root canal system [Trope 2006].

The traditional approach to handle cases with open apex is the multiple-visit apexification treatment with the use of calcium hydroxide (CH) as intracanal medicament [Seltzer, 1988]. The frequency of changes of CH from the root canal constitutes a controversial topic as there are studies that propose that a single placement of this medicament is enough to achieve predictable outcomes [Chawla 1986], whereas others claim that multiple replacements of CH could lead to a more rapid formation of a calcified tissue barrier [Abbot 1998]. The time required for the calcified tissue barrier to form varies from 5 to 20 months [Sheehy and Roberts, 1996] and seems to be influenced by several factors such as opening of the apex, frequency of intracanal medication replacement, age of the patient and the presence of periapical radiolucency [Mackie et al., 1988; Finucane and Kinirons, 1999; Kleier and Barr, 1991].

CH apexification has high clinical success rates and

Journal of the Formosan Medical Association (2016) 115, 523–530

Available online at www.sciencedirect.com

ScienceDirect

journal homepage: www.jfma-online.com



ORIGINAL ARTICLE

Comparison of mineral trioxide aggregate and calcium hydroxide for apexification of immature permanent teeth: A systematic review and meta-analysis

Jia-Cheng Lin, Jia-Xuan Lu, Qian Zeng, Wei Zhao, Wen-Qing Li, Jun-Qi Ling*

Guanghua School of Stomatology, Guangdong Provincial Key Laboratory of Stomatology, Sun Yat-sen University, Guangzhou, China

Received 6 November 2015; received in revised form 14 January 2016; accepted 20 January 2016

Indian Society of Dental Traumatology

- Steiner JC, Dow PR, Cathy GM. Inducing root end closure of non-vital permanent teeth. J Dent Child. 1968;35:57-9.
- Torabinejad M, Hong CU, McDonald F, Pitt Ford TR. Physical and chemical properties of a new root-end filling material. J Endod 1995;21:349-53.
- Frank AL. Therapy for the divergent pulpless tooth by continued apical formation. J Am Dent Assoc. 1966; 72: 87-93
- Shabahang S, Torabinejad M, Boyne PP, Abedi H, McMillan P.A comparative study of root-end induction using osteogenic protein-1, calcium hydroxide, and mineral trioxide aggregate in dogs. J Endod 1999;25:1-5.
- Steinig TH, Regan JD, Gutmann JL. The use and predictable placement of mineral trioxide aggregate in one- visit apexification cases. Aus Endod J. 2003; 29: 34-42.

Indian Society of Dental Traumatology

Tooth Avulsion

Dental Traumatology

Dental Traumatology 2010; **26**: 52–59; doi: 10.1111/j.1600-9657.2009.00836.x

Factors related to treatment and outcomes of avulsed teeth

Bojan Petrovic[1], Dejan Marković[2], Tamara Peric[2], Duska Blagojevic[1]

[1]Dentistry Clinic of Vojvodina, Novi Sad, Serbia
[2]Clinic for Paediatric and Preventive Dentistry, Faculty of Stomatology, Belgrade, Serbia

Abstract – *Background*: The aim of this study was to examine factors associated with avulsion injury and to specify the association between these factors and the treatment, as well as the outcomes of avulsed permanent incisors in children. *Materials and methods*: The sample consisted of 51 children with 62 avulsed permanent incisors, whose injuries had been managed in the period 1998–2006. The study was prospective, recording the history of the accident, concomitant injuries, age, gender, apical maturity of the root, replantation rate, storage media, extra-alveolar duration, endodontic treatment, compliance and recall appointments response. Factors were analysed in relation to postoperative outcomes, classified as functional healing (FH), infection-related (inflammatory) resorption (IRR) and replacement resorption (*RR*). *Results*: The average age of patients was 10.7 years (range 7–19). In 16/51 patients, tooth avulsion was caused by a road traffic accident. Avulsion was accompanied by concomitant injuries in all cases. Thirty of 62 avulsed teeth were not replanted and 32 incisors were replanted after dry storage. Time until replantation ranged between 15 min and 9 h (median 60 min). The observation period ranged from 1 to 6 years (median 2 years). FH was observed in 5/32, IRR in 20/32 and RR in 7/32 incisors. Ten teeth were extracted during 5-years of observation. Immature incisors exhibited significantly more complications compared with mature teeth ($P = 0.04$). Storage media and extra-alveolar duration did not significantly

Indian Society of Dental Traumatology

Oral Health Dent Manag. 2014 Jun;13(2):229-42.

Strategies to minimise the consequences of trauma to the teeth.

Abbott PV[1], Salgado JC.

J Endod. 2017 Nov;43(11):1792-1796. doi: 10.1016/j.joen.2017.06.027. Epub 2017 Aug 14.

Types of External Root Resorption of Replanted Teeth: Analysis of the Clinical Aspects and of Interleukin-4 Gene Polymorphisms Involvement.

Roskamp L[1], Trevilatto PC[2], Souza CM[2], Silva Neto UX[2], Carneiro E[2], Fariniuk LF[2], Westphalen VPD[2].

Endod Dent Traumatol. 1995 Apr;11(2):76-89.
Replantation of 400 avulsed permanent incisors. 4. Factors related to periodontal ligament healing.
Andreasen JO[1], Borum MK, Jacobsen HL, Andreasen FM.

Endod Dent Traumatol. 1995 Apr;11(2):69-75.
Replantation of 400 avulsed permanent incisors. 3. Factors related to root growth.
Andreasen JO[1], Borum MK, Andreasen FM.

Endod Dent Traumatol. 1995 Apr;11(2):59-68.
Replantation of 400 avulsed permanent incisors. 2. Factors related to pulpal healing.
Andreasen JO[1], Borum MK, Jacobsen HL, Andreasen FM.

Aust Endod J. 2012 Dec;38(3):129-36. doi: 10.1111/j.1747-4477.2012.00356.x. Epub 2012 Jun 1.

Transport media for avulsed teeth: a review.

Udoye CI[1], Jafarzadeh H, Abbott PV.

Indian Society of Dental Traumatology

Healing Complications

Australian Dental Journal
The official journal of the Australian Dental Association
ADA AUSTRALIAN DENTAL ASSOCIATION INC.
Australian Dental Journal 2016; 61:(1 Suppl): 82–94
doi: 10.1111/adj.12400

Prevention and management of external inflammatory resorption following trauma to teeth

PV Abbott

Dental Traumatology 2002; 18: 116–128
Printed in Denmark . All rights reserved

Review Article

Effect of treatment delay upon pulp and periodontal healing of traumatic dental injuries – a review article

J.O. Andreasen, F.M. Andreasen,
A. Skeie, E. Hjørting-Hansen,
O. Schwartz

Andreasen JO, Andreasen FM, Skeie A, Hjørting-Hansen E, Schwartz O. Effect of treatment delay upon pulp and periodontal healing of traumatic dental injuries – a review article. Dent

Indian Society of Dental Traumatology

Best of Luck for Exam of Life

International Association of Dental Traumatology

Indian Society of Dental Traumatology

dr.nitesht@gmail.com